

*Excerpt from the Prenatal Screening for Down Syndrome, Trisomy 18, and Open Neural Tube Defects Guideline  
October 2020*

## Soft Markers Identified on Detailed Ultrasound

Several markers identified on second-trimester ultrasound examination are associated with increased risk of Down syndrome. The markers are not equally suggestive of Down syndrome. Based on the presence or absence of these markers, positive or negative likelihood ratios can be applied to the risk calculation for Down syndrome from SIPS/IPS/Quad allowing modification of a patient's risk. Some markers are also indicative of increased risk of condition(s) other than Down syndrome.

### Markers that significantly increase the risk of Down syndrome include:

- increased nuchal thickness (NTh)  $\geq 6$  mm
- echogenic bowel (equal or greater than bone)
- ventriculomegaly
- **absent** nasal bone (second trimester) (not routinely looked for)
- aberrant right subclavian artery (not routinely looked for)

### Markers with only a small impact on the risk of Down syndrome include:

- echogenic intracardiac focus (EICF)
- pyelectasis (5 mm–10 mm)
- abnormal femur/foot ratio ( $\leq 0.9$ ).

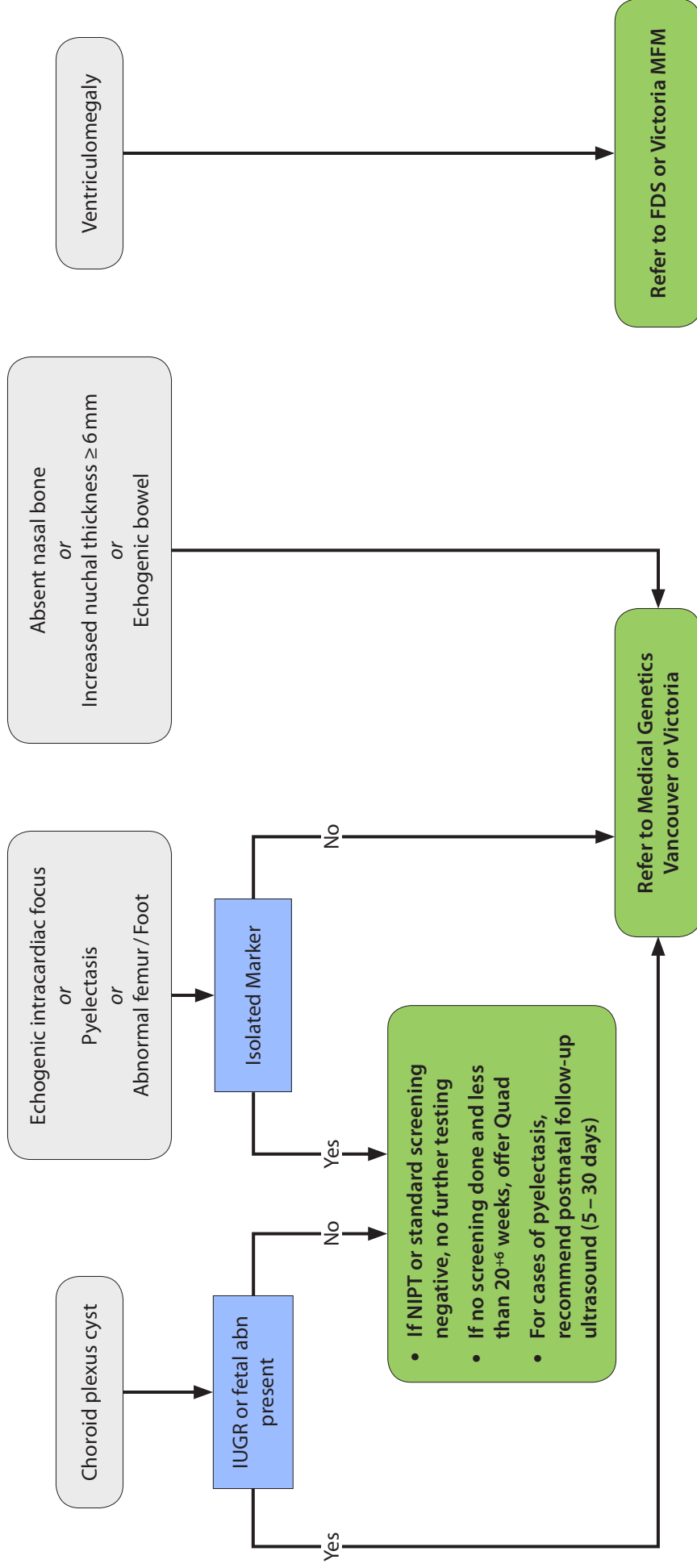
### Markers that increase the risk of condition(s) other than Down syndrome include:

- increased nuchal thickness (NTh)  $\geq 6$  mm
- echogenic bowel
- ventriculomegaly
- pyelectasis (5 mm–10 mm)

### Recommended management:

1. If ultrasound detects NTh  $\geq 6$  mm, echogenic bowel (brightness  $\geq$  bone), **absent** nasal bone (second trimester), aberrant right subclavian artery, or more than one marker, referral to Medical Genetics is recommended.
2. If ultrasound detects ventriculomegaly, referral to the Fetal Diagnosis Service is recommended.
3. If ultrasound detects isolated pyelectasis, abnormal femur/foot ratio ( $\leq 0.9$ ) or echogenic intracardiac focus (EICF), and the Down syndrome screen (SIPS/IPS/Quad or NIPT) showed a negative screen (low risk), no further prenatal testing is recommended. If no screening has been done and patient is less than 20 weeks and 6 days gestation, Quad screening should be offered.
4. If ultrasound detects pyelectasis, a postnatal renal ultrasound between 5–30 days of age is recommended.
5. If Choroid plexus cyst (CPC) is detected, referral to Medical Genetics is recommended **only** if CPC is seen in combination with structural abnormalities or growth restriction. No further testing is indicated if CPC is identified in isolation and the patient's SIPS/IPS/Quad or NIPT is screen negative for trisomy 18 (for SIPS/IPS/Quad, risk only appears on report when screen positive). If no screening has been done and patient is less than 20 weeks and 6 days gestation, Quad screening should be offered.

# Soft Markers on 2nd Trimester Ultrasound



Medical Genetics	Fetal Diagnosis Service (FDS)	Maternal Fetal Medicine
Vancouver: T: 604-875-2818 F: 604-875-3484	Victoria: T: 250-727-4461 F: 250-727-4295	BC Women's Hospital: T: 604-875-2162 F: 604-875-3255
		Surrey Jim Pattison: T: 604-582-4558 ext. 763995 F: 604-582-3798
		Victoria General: T: 250-727-4266 F: 250-727-4441